Directly Coded Summary Stage

Melanoma

Directly Coded Summary Staging

- Summary Stage is a basic way of categorizing how far a tumor has spread from its point of origin at the time of diagnosis.
- Summary Stage applies to every anatomic site, including the lymphomas and leukemia's.
- The staging categories are broad enough to measure the success of cancer control and other epidemiologic efforts.
- Summary Stage includes a combination of clinical and pathologic information on the extent of disease.
- Includes information within four (4) months of diagnosis through the completion of surgeries—whichever is longer.

Determining the Stage

- **Review of Medical Reports**
  - History and physical exam and work up documents
  - Operative and pathology reports
  - imaging reports for documentation of primary site and any spread
  - Pathology reports
  - Others
  - Make note of the “negative” as well as positive findings in your text
- **Review the anatomy of the site:**
  - Lymph nodes
  - Adjacent tissues/organs
  - Distant sites

Assigning the Correct Summary Stage Code

Nine possible codes for Summary Stage

- 0 = In-Situ
- 1 = Localized
- 2 = Regional disease by direct extension only
- 3 = Regional disease with only regional lymph nodes involved
- 4 = Regional disease by both direct extension and regional lymph node(s)
- 5 = Regional disease that is not otherwise specified
- 7 = Distant sites and/or distant lymph node involvement
- 8 = Benign and borderline CNS tumors
- 9 = Unknown if there is extension or metastatic disease (unstaged, death certificate only cases)

Important to note:

- SEER Summary Staging Manual 2000 includes:
  - Ambiguous Terminology – SEE pg. 15
    - Terms used to consider involvement

      Ex: "adherent to" or "probable"
    - Terms used that do not consider as involvement

      Ex: "attached" or "possible"

http://seer.cancer.gov/tools/ssm/

Important to note:

SEER Summary Staging Manual 2000 includes:

- General rules and guidelines
- Anatomy graphics
- A criteria list to assign each stage category in each chapter
- Notes included in sites that contain additional information
- Historical information for analyses--#

http://seer.cancer.gov/tools/ssm/

What Does Summary Stage In Situ Mean?
Code 0

- **In-Situ is defined as malignancy without invasion.**
  - Only occurs in carcinomas and melanomas
  - Must be microscopically diagnosed

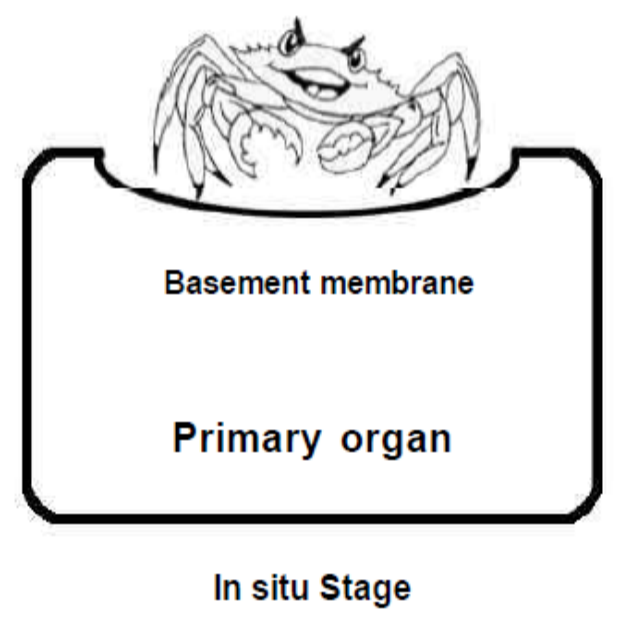

- **Note:**
  - *microinvasion* is *at least*
    localized or code 1
  - If there is nodal involvement or spread,
    the cancer cannot be in-situ

What Does Localized Summary Stage Mean? Code 1

- Malignancy is limited to organ of origin.
- No spread beyond the organ of origin.
- Infiltration past the basement membrane of epithelium into the functional part of the organ; however, there is no spread beyond the boundaries of the organ.

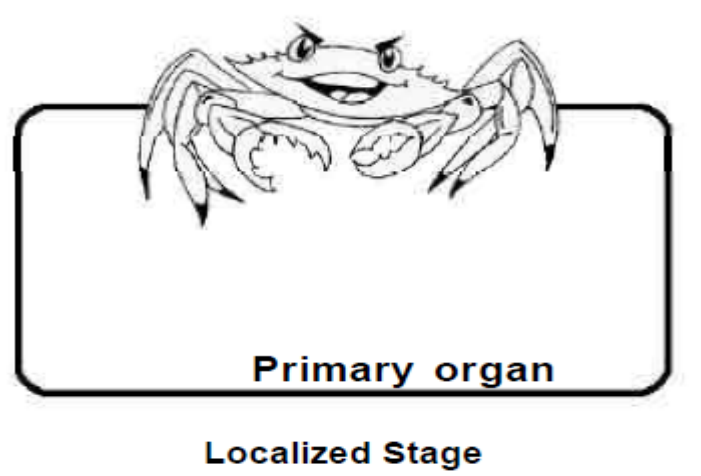

Source: SEER Summary Stage Manual - 2000

What Does Regional Disease Mean?

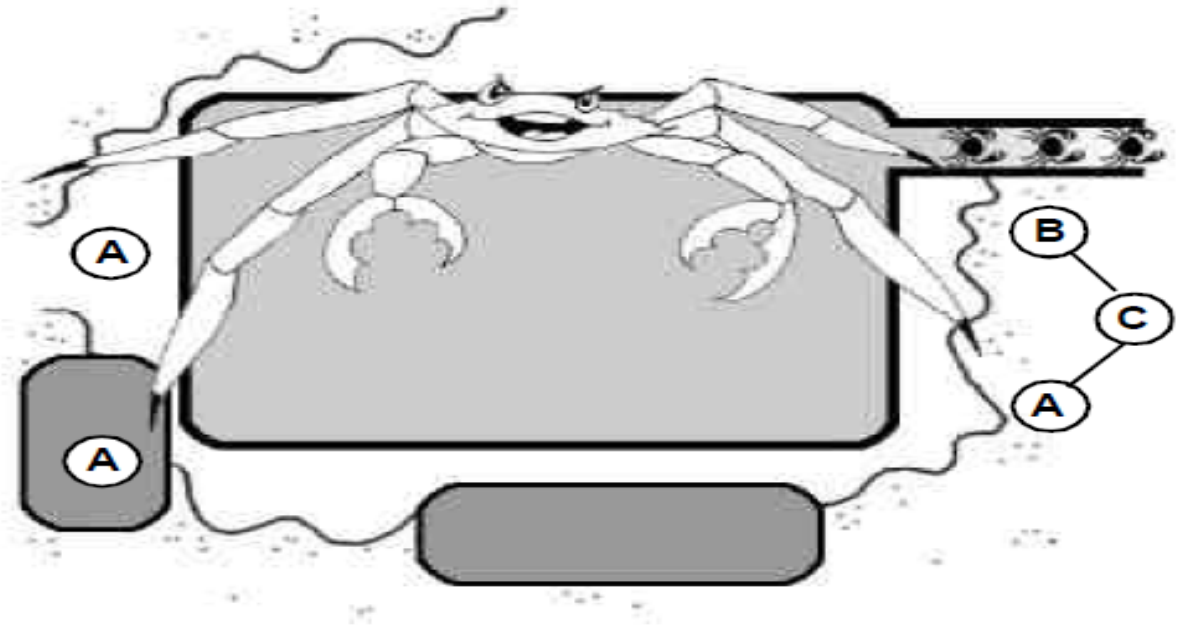

Regional Stages
A. Direct extension
B. To regional lymph nodes
C. Combination of A and B

Source: SEER Summary Stage Manual - 2000

What Does Regional Stage Mean?
Codes 2, 3, 4, or 5

- **Regional by direct extension (Code 2)**
  Tumor has invaded surrounding organ(s) or adjacent tissues. May also be referred to as direct extension or contiguous spread.
- **Regional to lymph nodes (Code 3)**
  Tumor cells may have traveled through the lymphatic system to regional lymph nodes where they remain and begin to "grow."
- **Regional by direct extension and lymph nodes (Code 4)**
  Extension into adjacent structures or organs and lymph node involvement are both present.
- **Regional, NOS (Code 5)**
  Regional spread or disease is the only information available

What does Distant Stage Mean?

(code 7)

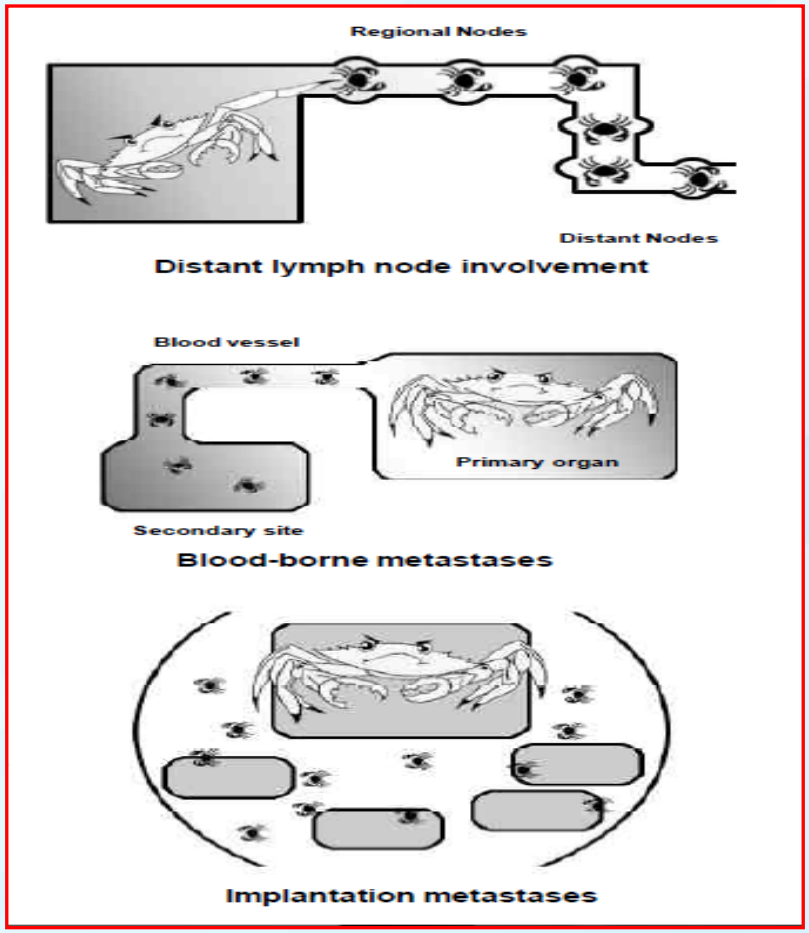

Source: SEER Summary Stage Manual - 2000

What does Distant Summary Stage Mean?
Code 7

Distant Stage indicates that the tumor has spread to areas beyond the regional sites.

- **These sites may be called:**
  - **Remote**
  - **Metastatic**
  - **Diffuse**
- **Distant lymph nodes are those that are not included in the drainage area of the primary tumor.**
- **Hematogenous metastases develop from tumor cells carried by the bloodstream and begin to grow beyond the local or regional areas.**

General Tips for the Abstractor

- Distant disease is documented, no need for further chart review
- Pathology reports that contain a statement of invasion, nodal involvement or metastatic spread, in situ stage is ruled out *even when the path reports states "in situ"*
- If there are nodes involved, the stage must be at least regional to lymph nodes
- Any unidentified nodes included with the pathology specimen of primary site are considered regional nodes

General Tips for the Abstractor

- **Ignore lymph node terms**
  - Palpable
  - Visible swelling
  - Shotty
- **Ignore lymph node terms (*except for lung primaries)***
  - Enlarged
  - Lymphadenopathy
- **Consider lymph node involvement for solid tumors**
  - Fixed
  - Matted
  - Mass in the mediastinum
  - Retroperitoneum and/or
  - Mesentary

General Tips for the Abstractor

- **Distinguishing the difference between direct extension and distant metastases:**
  - Secondary site, tumor ON the surface, most likely direct extension
  - Secondary site, tumor IN the organ, distant spread
- **Unknown stage:**
  - If the record does not contain enough information to code a stage, it must be recorded as unstageable
  - Unknown primary/unknown stage (Code 9)
  - Use sparingly and only when absolutely necessary
- **Code 8**
  - Limited to benign/borderline CNS tumors

Melanoma
Review of Medical Information

- **History and Physical Exam**
  - Location and appearance of lesion
- **Imaging Reports**
  - Lymph node involvement
  - Regional or distant spread
- **Operative Reports**
  - Primary tumor description and excision
  - Lymph node excision
- **Pathology Reports**
  - Thickness (Breslow's)
  - Level of invasion (Clark's)
  - Satellite lesions
  - Lymph node involvement

Melanomas

- Summary Stage Melanoma chapter also includes ICD-O codes *other than* C44._. For the skin of the following:
  - Vulva
  - Penis, and Scrotum
- Staging criteria is the same for all sites listed
- Regional lymph nodes are listed for each primary site within the melanoma chapter
- All melanoma skin sites:
  - Satellite nodules >2cm from primary site is Regional to Lymph Nodes
  - Satellite nodules ≤2cm from primary site is Regional by Direct Extension

Source: SEER Summary Stage Manual - 2000

Melanomas
Prognostic Factors (not part of Summary Stage)

- **Breslow's thickness**
- **Mitotic Rate**
  - Higher rates associated with:
    - more rapidly dividing cells,
    - larger lesions with greater potential for metastases
- **Skin ulceration**
- **Number of regional lymph nodes involved**

Important to document all of these items in your text!

Source: SEER Summary Stage Manual - 2000

Melanoma Prognostic Factor

Clark's Level and Stage

Clark's Level	Summary Stage
I	In Situ
II-IV	Local
V	Regional by Direct Extension only

Melanoma Prognostic Factors

Local Stage

Clark's Level	Breslow's thickness
II	<or=.75mm
III	.76 to1.50mm
IV	1.51mm-4mm

Clark's level V—at least Regional by Direct Extension

Melanomas

- **Discrepancy between Clark's level and path report**
  - Code to the higher (more extensive) Summary Stage
  - Document the discrepancy in the text

Source: SEER Summary Stage Manual - 2000

Anatomy of the Skin

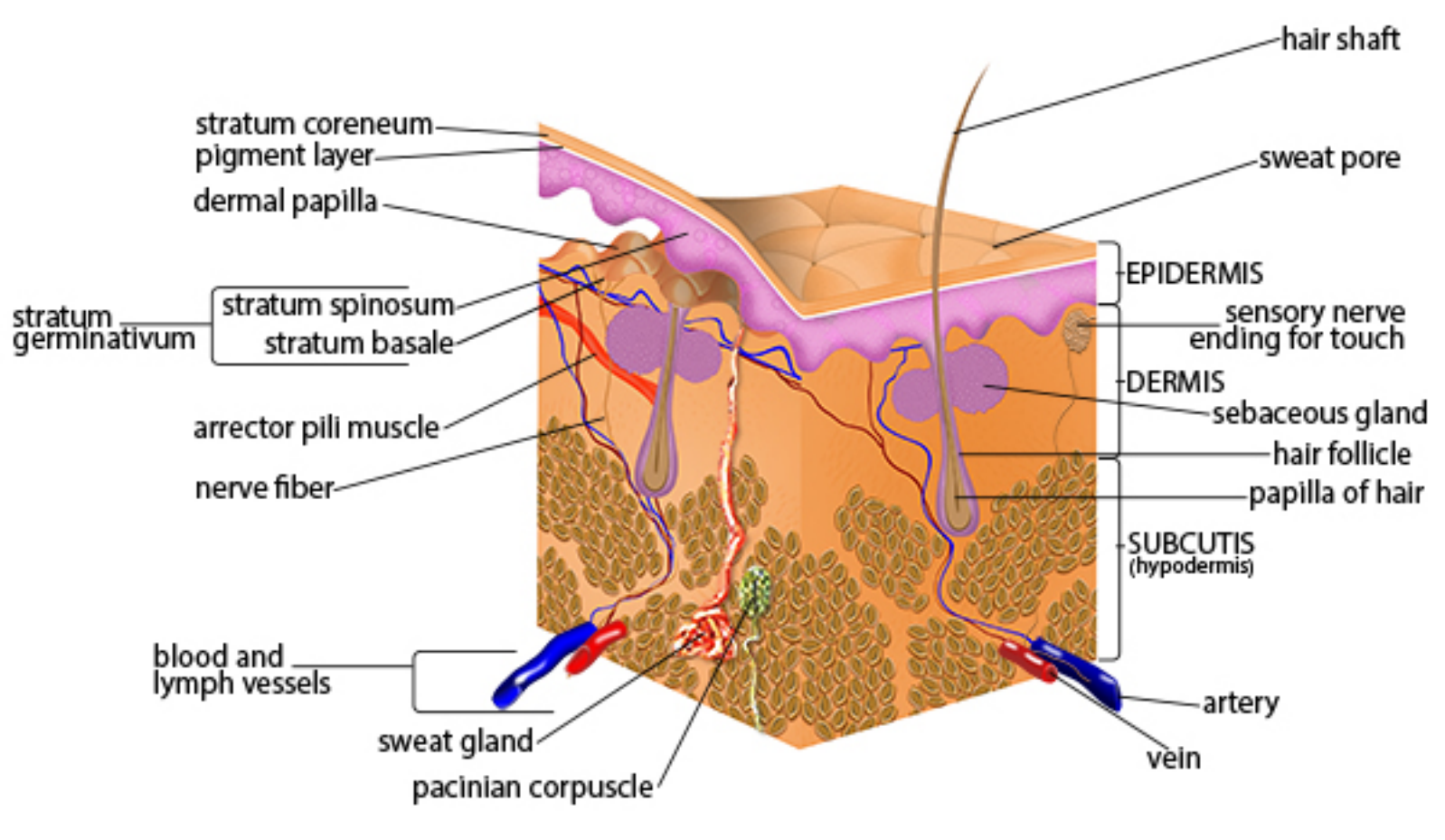

http://seer.cancer.gov/

Anatomy of the Skin

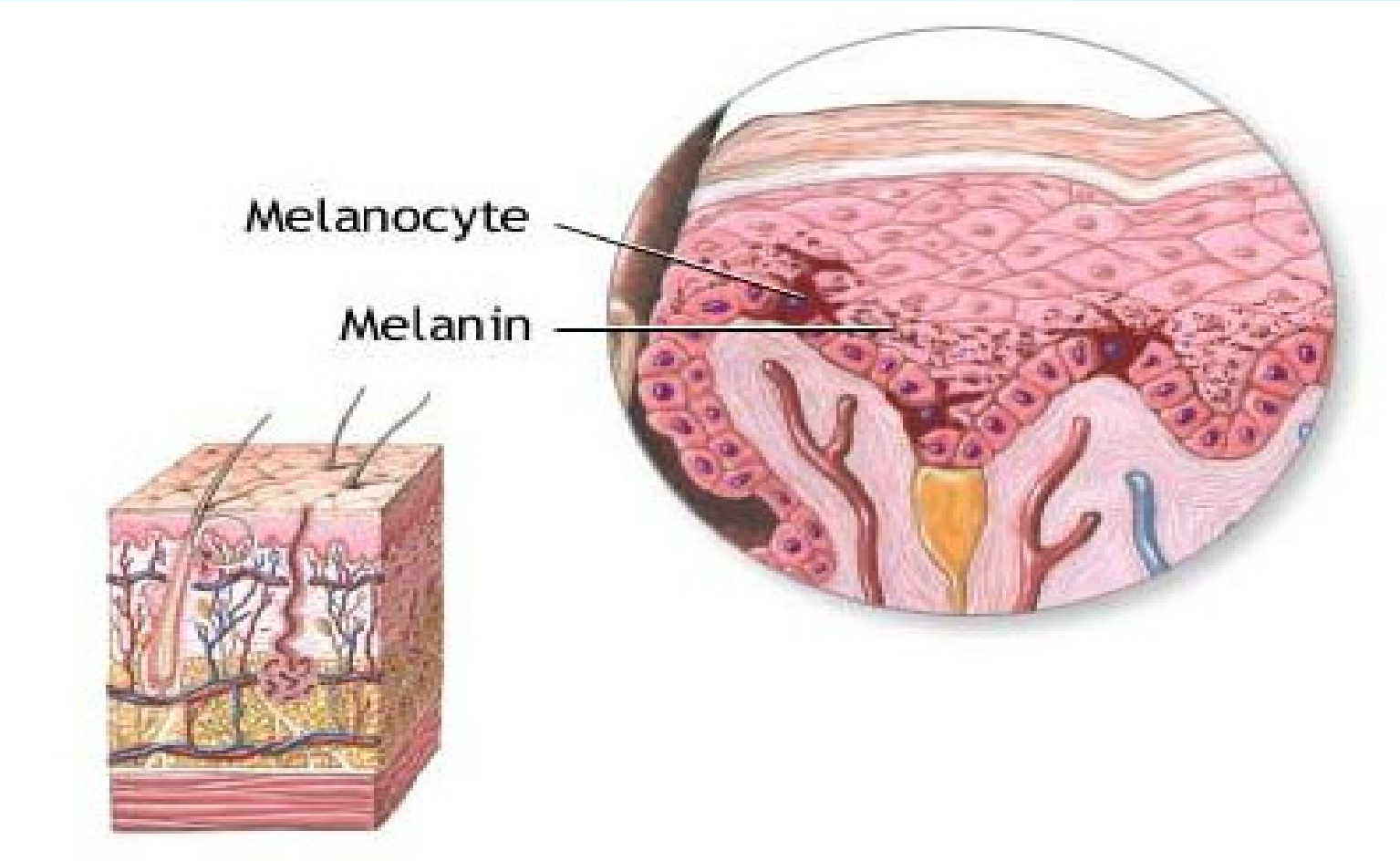

http://seer.cancer.gov/

In Situ Summary Stage Code 0

Melanoma common terms for in situ:

- Behavior code = 2
  - Intraepidermal
  - Clark's level 1
  - Lentigo maligna
  - Hutchinson melanotic freckle
  - Precancerous melanosis

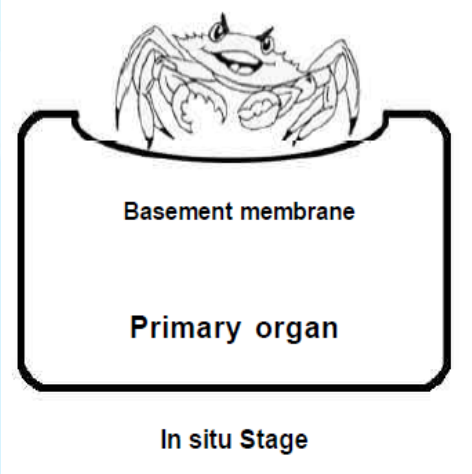

In Situ Lesion

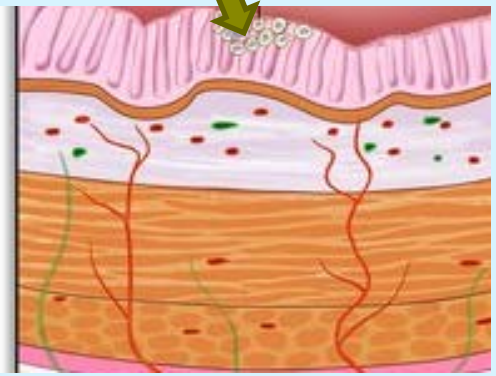

Source: SEER Summary Stage Manual - 2000

Local Summary Stage
Code 1

Localized Melanoma

- Behavior Code of 3
- Dermis is invaded
  - Papillary dermis Clark's II
  - Papillary-reticular dermis Clark's III
  - Reticular dermis Clark's IV
  - Skin/dermis, NOS
  - Localized, NOS

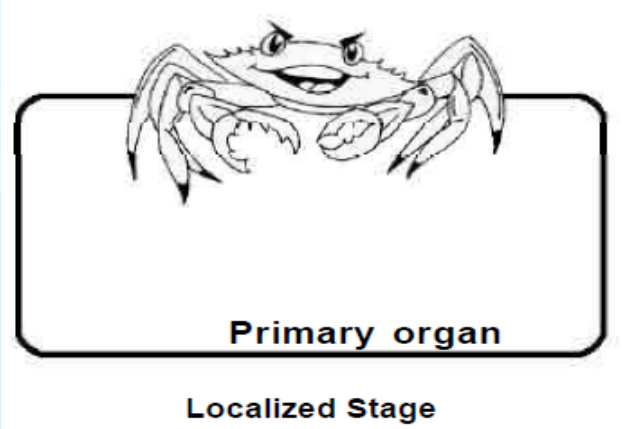

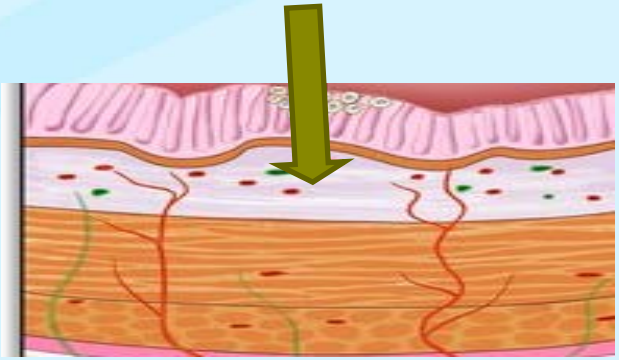

Invades the second layer--Dermis

Source: SEER Summary Stage Manual - 2000

Regional by Direct Extension Summary Stage Code 2

- **Subcutaneous tissue invaded**
  - Clark's level V
  - Entire dermis layer is invaded
- **Satellite nodule, NOS**
  - ≤2cm from primary

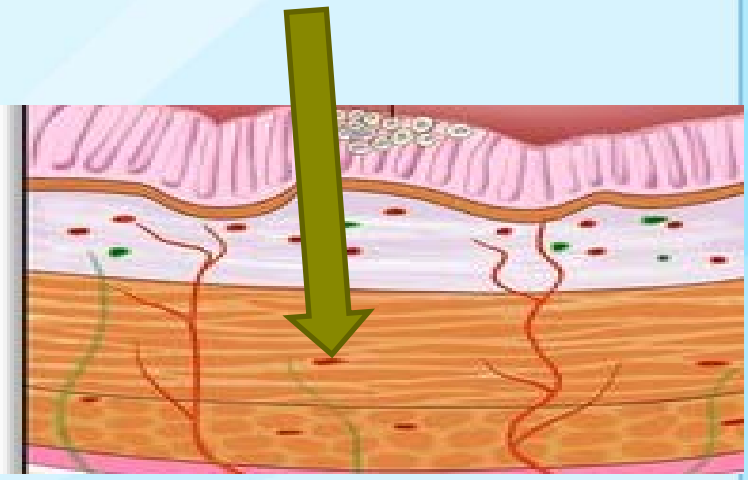

invades through the dermis into the Subcubis

Source: SEER Summary Stage Manual - 2000

Regional Lymph Nodes Summary Stage Code 3

- **Primary melanoma involves the regional lymph nodes (only)**
- **Regional Lymph Nodes are listed by the primary skin site**
- **Involved node is not listed for a skin site**
  - Look for synonymous terms—
    - Synonymous node names are Code 3
    - Non-synonymous are Code 7 or Distant Stage
- **In-transit metastasis (satellite nodules >2cm from the primary tumor**
- **Regional lymph nodes, NOS**

Source: SEER Summary Stage Manual - 2000

Regional by BOTH Summary Stage Code 4

- Melanoma involves BOTH
  - Penetration of entire dermis
  - Regional lymph nodes
- Satellite nodules BOTH
  - ≤2 cm from the primary
  - >2 cm from the primary

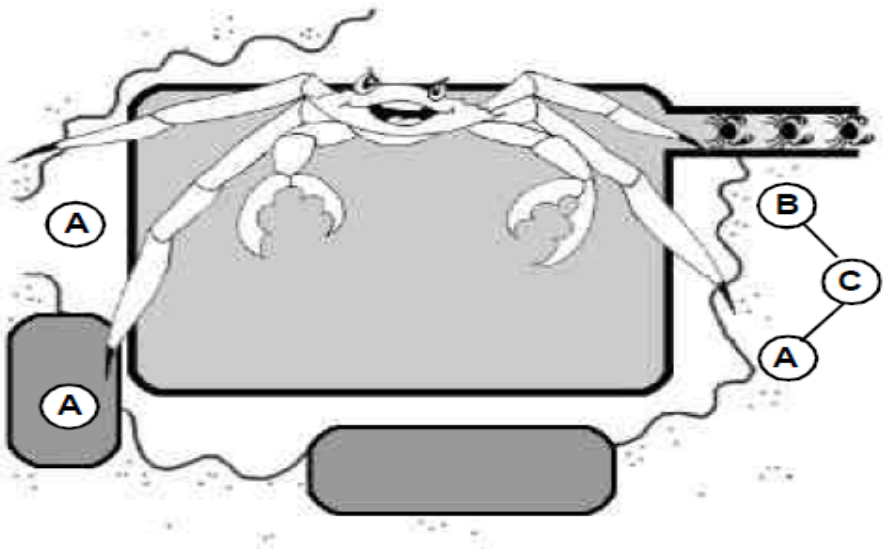

Regional Stages
A. Direct extension
B. To regional lymph nodes
C. Combination of A and B

Source: SEER Summary Stage Manual - 2000

Regional, NOS Summary Stage Code 5

- Regional Not Otherwise Specified
  - No information to assign:
    - Regional by Direct Extension-Code 2
    - Regional Lymph Nodes only-Code 3
    - Regional to BOTH-Code 4
  - Information is limited to “regional disease”

Wait—Before we move on…..

Regional Lymph Nodes for Melanoma of the Skin

Primary Site	Regional Lymph Nodes
Head and Neck	Cervical, NOS (for all)
Lip:	Facial, NOS: Buccinator (buccal) Nasolabial Mandibular, NOS: Submandibular (submaxillary) Submental Parotid, NOS: Infra-auricular Preauricular
Eyelid/canthus:	Facial, NOS: Buccinator(buccal) Nasolabial (continued next slide)

Regional Lymph Nodes for Melanoma of the Skin

Primary Site	Regional Lymph Nodes
Head and Neck	Cervical, NOS (for all)
Eyelid/canthus:	Mandibular, NOS: Submandibular (submaxillary) Submental Parotid, NOS: Infra-auricular
External ear/auditory canal:	Mastoid (post-/retro-auricular) Preauricular
Face, Other: (cheek, chin, forehead, jaw, nose, temple)	Facial, NOS; Buccinator (buccal) Nasolabial (continued next slide)

Regional Lymph Nodes for Melanoma of the Skin

Primary Site	Regional Lymph Nodes
Head and Neck	Cervical, NOS (for all)
Face, Other: (cheek, chin, forehead, jaw, nose, temple)	Mandibular, NOS: Submandibular (submaxillary) Submental Parotid, NOS: Infra-auricular Preauricular
Scalp:	Mastoid (post-/retro-auricular) Parotid, NOS Infra-auricular Preauricular Spinal Accessory (posterior cervical)

Regional Lymph Nodes for Melanoma of the Skin

Primary Site	Regional Lymph Nodes
Head and Neck	Cervical, NOS (for all)

Neck:	Axillary
	Mandibular, NOS:
	  Submental
	Mastoid (post-/retro-auricular)
	Parotid, NOS:
	  Infra-auricular
	  Preauricular
	Spinal Accessory (posterior cervical)
	Supraclavicular (transverse cervical)

Upper trunk:	Axillary Cervical Internal mammary Supraclavicular (transverse cervical)

Regional Lymph Nodes for Melanoma of the Skin

Primary Site	Regional Lymph Nodes
Lower Trunk:	Superficial inguinal (femoral)
Arm/Shoulder:	Axillary Epitrochlear for **hand/forearm** Spinal accessory (posterior cervical) **for shoulder**
Leg/hip:	Popliteal **for heel and calf** Superficial inguinal (femoral)
Vulva/penis/scrotum:	Deep inguinal, NOS: Node of Cloquet or Rosenmuller (highest deep inguinal Superficial inguinal (femoral)
All sites:	In-transit metastasis (satellite nodules >2 cm from primary) Regional lymph node(s), NOS

Distant Summary Stage
Code 7

- Distant lymph nodes
- Further contiguous extension:
  - Cartilage
  - Bone
  - Skeletal muscle
- Metastasis
  - Skin or subcutaneous tissue beyond regional lymph nodes
  - Visceral metastasis
  - Other organs

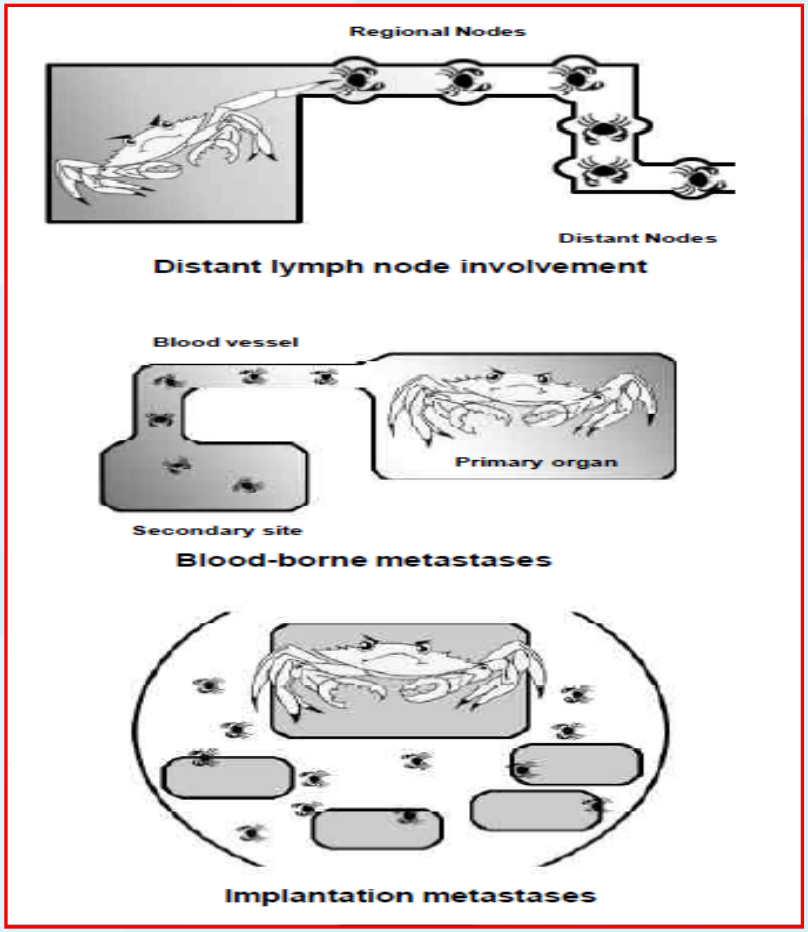

Source: SEER Summary Stage Manual - 2000

Refer to the online manuals regularly and periodically check the site for updates and/or changes

http://seer.cancer.gov/tools/ssm/

Exercise 1 – How would you stage this?

History and Physical:
Lesion noted on the right shoulder. Irregular borders, and no ulceration.

Treatment:
Wide excision

Pathology:
Lentigo Maligna skin of the right shoulder
Clark's level I

Exercise 1 – How would you stage this?

History and Physical:
Lesion noted on the right shoulder. Irregular borders, and no ulceration.

Treatment:
Wide excision

Pathology:
Lentigo Maligna skin of the right shoulder
Clark's level I

Answer: Summary Stage In Situ (Code 0) – Lentigo Maligna and Clark's level I indicative of an In Situ Melanoma

Text: Lentigo Maligna, Clark's level I, right shoulder, no ulceration, complete excision

Exercise 2 – How would you stage this?

During a routine physical exam, a fifty one year old female was found to have an ulcerated lesion on the left upper arm highly suspicious for melanoma. Satellite nodules approximately 1.5 cm from the lesion on the upper arm. No axillary nodes palpable and CT Scan did not indicate any lymph node or distal involvement.

She underwent a wide excision of the primary and a biopsy of both satellite nodules.

Pathology:
Clark's level V ulcerated melanoma.
Two satellite nodules – malignant melanoma

Exercise 2 – How would you stage this?

During a routine physical exam, a fifty one year old female was found to have an ulcerated lesion on the left upper arm highly suspicious for melanoma. Satellite nodules approximately 1.5 cm from the forearm lesion. No axillary nodes palpable and CT Scan did not indicate any lymph node or distal involvement.

She underwent a wide excision of the primary and a biopsy of both satellite nodules.

Pathology:
Clark's level V ulcerated melanoma.
Two satellite nodules – malignant melanoma

Answer: Summary Stage Regional by Direct Extension (Code 2) – Clark's level V and Satellite nodules equal to or less than 2 cm are assigned Regional by Direct Extension

Text: Ulcerated melanoma Clark's level V and satellite nodules less than 2 cm from primary completely excised. CT Scan negative for any nodal or distant involvement.

Exercise 3 – How would you stage this?

A 70 year old male presented with a nodular appearing dark lesion on the skin of the face, right mandibular area. Palpable nodes in the preauricular and submandibular area. Patients family reports that the patient seems to have bouts of confusion that are increasing with time.

Excisional biopsy confirms a nodular melanoma. Breslow's measurement greater than 1.8 mm. Sentinel lymph node biopsy positive for malignant melanoma, submaxillary.
CT Scan of the brain indicates multiple lesions consistent with malignant melanoma.

Exercise 3 – How would you stage this?

A 70 year old male presented with a nodular, ulcerated dark lesion on the skin of the face, right mandibular area. Palpable nodes in the preauricular and submandibular area. Patients family reports that the patient seems to have bouts of confusion that are increasing with time.

Excisional biopsy confirms a nodular melanoma. Breslow's measurement greater than 1.8 mm. Sentinel lymph node biopsy positive for malignant melanoma, submaxillary.
CT Scan of the brain indicates multiple malignant lesions consistent with malignant melanoma.

Answer: Summary Stage Distant (Code 7)—metastases to the brain

Text: CT Scan of the brain consistent with malignant melanoma. Primary was ulcerated, Breslow's 1.8mm and two positive sentinel nodes.

Exercise 4 – How would you stage this?

A 35 year old female seen for a mole on the left upper thigh. Mole has been present "several years" but recently seems to be enlarging and color is "darkening".

Biopsy: Malignant melanoma.
Wide excision and sentinel nodes:
Malignant melanoma with 2cm radial margins. Breslow's 3mm
Femoral Sentinel nodes (2) positive for malignant melanoma

MRI: enlarged superficial inguinal nodes, no other areas indicate involvement (of melanoma)

Complete resection of femoral nodes, 02 of 06 nodes positive for malignant melanoma.

Patient referred for systemic therapy.

Exercise 4 – How would you stage this?

A 35 year old female seen for a mole on the left upper thigh. Mole has been present "several years" but recently seems to be enlarging and color is "darkening".

Biopsy: Malignant melanoma.
Wide excision and sentinel nodes:
Malignant melanoma with 2cm radial margins. Breslow's 3mm, Clark's level V
Femoral Sentinel nodes (2) positive for malignant melanoma

MRI: enlarged superficial inguinal nodes, no other areas indicate involvement (of melanoma)

Complete resection of femoral nodes, 02 of 06 nodes positive for malignant melanoma. Patient referred for systemic therapy.

Answer: Regional by BOTH direct extension and lymph nodes –(Code 4), Clark's level V + positive regional lymph nodes.

Text: Malignant melanoma, Clark's level V, Breslow's 3mm, 2 of 6 nodes positive. MRI- no other involvement

Exercise 5 – How would you stage this?

A 41 year old female seen for a routine skin examination. Area noted on the left forearm, dark in places with irregular borders. Area was not noted on last year's exam.

Excisional Biopsy: Malignant melanoma.
Breslow's 1.3mm
Clark's Level III
Margins negative

Patient to return in six months.

Exercise 5 – How would you stage this?

A 41 year old female seen for a routine skin examination. Area noted on the left forearm, dark in places with irregular borders. Area was not noted on last year's exam.

Excisional Biopsy: Malignant melanoma.
Breslow's 1.3mm
Clark's Level III
Margins negative

Patient to return in six months.

Answer: Localized stage – Code 1
Text: Breslow's 1.3mm, Clark's Level III with negative margins

The CDC gratefully acknowledges
Terese Winslow for granting permission to incorporate her illustrations into this presentation.

Centers for Disease Control and Prevention
Chamblee Campus, Atlanta GA

Presentation created by CDC
For questions, please contact your designated CDC/NPCR Education Training Coordinator:

Donna M. Hansen, CTR
Auditor/Trainer
UC Davis Institute of Population Health
California Cancer Registry
1631 Alhambra Blvd, Suite #200
Sacramento, CA 95816
(916) 731-2543

Email: dhansen@ccr.ca.gov

For more information please contact Centers for Disease Control and Prevention

1600 Clifton Road NE, Atlanta, GA 30333
Telephone, 1-800-CDC-INFO (232-4636)/TTY:1-888-232-6348
E-mail: cdcinfo@cdc.gov Web:www.cdc.gov